Clinical Investigation

JOURNAL OF ENDOVASCULAR THERAPY
A SAGE Publication
An official publication of the ISEVS

Journal of Endovascular Therapy
1–7
© The Author(s) 2020
Article reuse guidelines:
sagepub.com/journals-permissions
DOI: 10.1177/1526602820931787
www.jevt.org
SAGE

Aortic Arch Anatomy Pattern in Patients Treated Using Double Homemade Fenestrated Stent-Grafts for Total Endovascular Aortic Arch Repair

Lucien Chassin-Trubert, MD[1], Thomas Gandet, MD[1], Baris Ata Ozdemir, FRCS, PhD[1], Youcef Lounes, MD[1], Pierre Alric, MD, PhD[1], and Ludovic Canaud, MD, PhD[1] [GQ: 1]

Abstract

Purpose: To analyze the structural variation of the aortic arch and the supra-aortic arteries and establish an average spatial configuration that would be a pattern for a "universal double fenestration" design for physician-modified endovascular grafts (PMEGs) used in total thoracic endovascular aortic repair (TEVAR). **Materials and Methods:** Aortic arch morphology was retrospectively analyzed by reviewing the preoperative thoracic computed tomography angiography scans in 33 consecutive patients (mean age 68 years; 27 men) treated between January 2017 and March 2019 using double-fenestrated PMEGs for zone 0 TEVAR. Image analysis was completed according to a standardized technique on a vascular workstation with center lumen line reconstruction for all measurements. Variations in branching pattern of the aortic arch were classified into 8 types. **Results:** The arch trunk configuration was type I in 26 patients (79%), type II in 5 (15%), type III in 1, and type IV in 1. Mean aortic diameters at the level of mid ascending aorta, innominate artery (IA), left common carotid artery (LCCA), and left subclavian artery (LSA) were 35.7±3.7, 34.2±4.5, 33.3±6.7, and 33.7±4.7 mm, respectively. Mean diameters of the trunk were 12.2±1.7, 7.5±1.4, and 8.0±0.8 mm, respectively. Mean longitudinal center to center lengths were 15.9±2.5 mm between the LSA and LCCA and 12.1±3.0 mm between the LCCA and IA. Mean clock positions using the LSA as reference were 12:50 for the IA and 12:05 for the LCCA. In 32 patients (97%) all the supra-aortic branch vessels fit perfectly inside two delimited areas defined by a proximal common square area of 30×30 mm for the IA and LCCA and a second distal circular area of 8 mm diameter for the LSA. **Conclusion:** Variations of the aortic arch anatomy are numerous and common. A general morphological pattern is described that delimits the aortic area where these variations occur. This information can be utilized for the design of an off-the-shelf double-fenestrated stent-graft for zone 0 TEVAR.

Keywords

aortic arch, aortic arch morphology, anatomy, fenestrated stent-graft, innominate artery, left common carotid artery, left subclavian artery, supra-aortic branches, surgeon-modified stent-graft, thoracic aorta, thoracic endovascular aortic repair, zone 0 landing

Introduction

Custom physician modification of aortic stent-grafts for branch vessel preservation is an alternative treatment strategy for arch lesions. It is generally utilized in patients who are otherwise not candidates for open surgery and did not have a proximal landing zone for endovascular treatment, especially in the urgent scenario.[1–6] Fenestrations are added to a standard commercial stent-graft to accommodate patient-specific vessel origins, thereby extending the landing zone proximally. Total endovascular arch repair can be achieved without compromise of the blood supply to the upper extremities, head, and neck using these physician-modified endovascular grafts (PMEGs).

[1]Department of Thoracic and Vascular Surgery, Arnaud de Villeneuve Hospital, Montpellier, France

Corresponding Author:
Lucien Chassin-Trubert, Service de Chirurgie Vasculaire et Thoracique, Hôpital A de Villeneuve, 191 av Doyen Gaston Giraud, Montpellier, 34090, France.
Email: info@cirujanovascular.cl

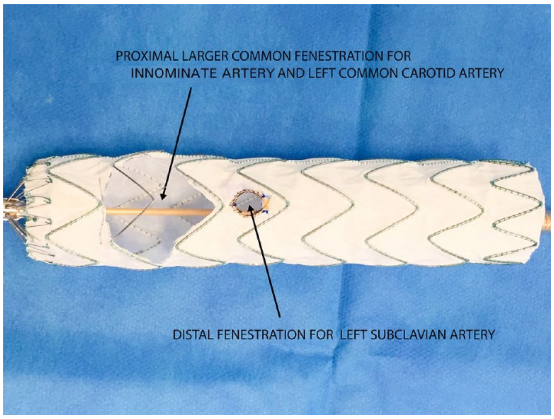

Figure 1. Physician-modified 38×38×167-mm Valiant Captivia thoracic stent-graft, with a common proximal large fenestration for the innominate and left common carotid arteries and a second distal fenestration for the left subclavian artery.

Multiple variations of aortic arch anatomy are shared among patients. Development occurs through a complex multistage process during the first weeks of fetal life. Changes in arch anatomy occur due to variation of this sequence. In the classical anatomical configuration, the aortic arch is left sided and has 3 branches from proximal to distal [innominate artery (IA), left common carotid artery (LCCA), and the left subclavian artery (LSA)]. The degree of variation of the aortic arch branching pattern may be significant. Both the origins and number of vascular structures can vary. Even when the aortic arch has a "normal pattern" the distribution of these 3 branches can deviate in distance, position, and takeoff angle.[7] These "normal patterns" are frequently encountered in clinical practice. Multidetector computed tomographic (CT) scanners are currently the preferred technology for aortic imaging, and a thin-slice (≤1 mm) CT angiogram (CTA) of the chest best characterizes the aortic arch and determines branch anatomy.[8]

Understanding these variations is essential to plan PMEGs with fenestrations. Our experience with double-fenestrated PMEGs to enable proximal landing in zone 0 started in January 2017. These stent-grafts have 2 fenestrations: one proximal, large opening for the IA and the LCCA (2 mm larger laterally than the diameters of the IA and LCCA orifices) and 1 distal fenestration for the LSA (Figure 1). Indication, preparation, technique, and results of our double-fenestrated PMEG program have been published in previous reports[4,5] and are summarized in Table 1.

This study sought to analyze morphological reference data to determine the structural variations of the aortic arch and the supra-aortic arteries. By establishing an average spatial configuration of the aortic trunks, a "universal double fenestration" design could be established to guide production of an off-the-shelf stent-graft to treat aortic arch lesions with proximal landing in zone 0.

Table 1. Indications and Results of Double-Fenestrated Physician-Modified Endovascular Grafts in 33 Patients.[a]

Indication	
Postdissection aortic aneurysm	12 (36)
Degenerative aortic aneurysm	11 (33)
Penetrating aortic ulcer	4 (12)
Acute complicated type B dissection	3 (9)
Aortic arch floating thrombus	1 (3)
Pseudoaneurysm	1 (3)
Aberrant right subclavian artery with Kommerell diverticulum	1 (3)
Results	
Mortality	1 (3)
Stroke	1 (3)
Type I endoleak	0
Technical failure	3 (9)
Follow-up, mo	10±6

[a]Continuous data are presented as the mean ± standard deviation; categorical data are given as the number (percentage).

Materials and Methods

Study Design

A retrospective analysis was conducted of the CTA data on aortic arch morphology and aortic length from 33 consecutives patients (mean age 68 years; 27 men) treated between January 2017 and March 2019 using PMEGs with double fenestrations for TEVAR landing in zone 0 (Video 1; available in the online version of the article). All patients were at high surgical risk owing to serious comorbidities (American Society of Anesthesiologists score ≥III or emergent repair).

Double-fenestrated PMEGs were considered for patients with zone 1 aortic arch lesions or zone 0 saccular aneurysms on the lesser curvature of the arch if the lengths of the proximal and distal necks were at least 20 mm and if the proximal and distal neck diameters were between 20 and 40 mm. Zone 0 aortic arch lesions, except saccular aneurysms on the lesser curvature of the arch, were deemed unsuitable because the size of the proximal fenestration was proximally and laterally larger than that of the IA and LCCA orifices, increasing the risk of endoleak. In aneurysms involving the greater curve in zone 0 it is preferable to use a custom branched stent-graft rather than a fenestrated PMEG.

The risks and benefits of treatment with off-the-shell PMEGs were explained to all patients before they signed the informed consent. Our study was approved by the ethical committee of the Arnaud de Villeneuve Hospital (MPL-2019-16).

Imaging

All patients underwent high-resolution CTA of the thorax preoperatively using a 256-slice CT scanner (Revolution CT; GE Healthcare, Waukesha, WI, USA) with a 0.6-mm

section thickness and 80 mL of contrast. Image analysis was completed according to a standardized measurement technique and was assessed by 2 vascular surgeons with experience of commercially available fenestrated stent-grafts to ensure interobserver agreement. The CTA data were transferred to the EndoSize 3D vascular workstation (version 3.1.25; Therenva, Rennes, France/Nanjing, China) with center lumen line reconstruction for all measurements. The ascending aortic diameter was measured in the mid-ascending aorta halfway between the sinotubular junction and aortic arch at the level of the right pulmonary artery. The aortic diameter was also measured at the level of each supra-aortic branch vessel. Diameters of the supra-aortic branch ostia were measured outer edge to outer edge perpendicular to the centerline of flow. The aortic arch configuration was further mapped by measuring the distances from the center of the LSA to the center of the LCCA and then from the center of the LCCA to the center of the IA along the greater curve. The proximal and distal edges between the LSA, LCCA, and IA along the greater curve were also recorded. The clock-face orientation of each branch vessel was captured using the center of the LSA as reference point at 12 o'clock (0° angle). The arch length of each supra-aortic branch vessel was calculated (Figure 2). The theoretical arc length was calculated according to the following formula: arc length = (degree/360) $\times$ $2\pi r$, where degree is calculated from the clock position hour and r is the radius of the aorta at the level of the branch vessel. Variations in branching pattern of the aortic arch were classified into 8 types (Table 2) according to the system proposed by Natsis et al.[9]

The study data were collected to generate descriptive statistics. Continuous variables are expressed as mean $\pm$ standard deviation and categorical variables as the number (percentage).

Results

Of the 33 arches evaluated, 26 (79%) had a type I and 5 (15%) had a type II aortic arch vessel trunk configuration (Table 2). There was only 1 patient with a type III and another patient with a type V aortic arch branching pattern.

The mean mid-ascending aortic diameter was 35.7$\pm$3.7 mm (Table 3). The mean aortic diameters at the levels of the IA, LCCA, and LSA where 34.2$\pm$4.5, 33.3$\pm$6.7, and 33.7$\pm$4.7 mm, respectively. The mean diameters of the branch vessels were 12.2$\pm$1.7 mm for the IA, 7.5$\pm$1.4 mm for the LCCA, and 8.0$\pm$0.8 mm for the LSA. The mean longitudinal length between the center of the LSA and the center of the LCCA were 15.9$\pm$2.5 mm; the center to center length between the LCCA and the IA was 12.1$\pm$3.0 mm. In addition, the mean longitudinal length between the proximal edge of the LSA to the distal edge of the LCCA was 7.7$\pm$2.4 mm; the corresponding measurement between the LCCA and IA was 22.3$\pm$3.3 mm. The mean clock positions for the supra-aortic branch vessels using the LSA as reference (12 o'clock or 0° angle) were 12:50 hours for the IA and 12:05 hours for the LCCA.

The structural variation of the aortic arch and spatial configuration of the supra-aortic arteries in the 33 patients using the origin of the LSA as the reference are shown in Figure 3A. The center of the supra-aortic trunk origins in all patients were contained within a proximal 30$\times$30-mm square area (IA and LCCA) and a second distal circular area of 8 mm diameter (LSA). The square and circular common areas are separated by 5 mm (Figure 3B).

When the diameter, longitudinal distance between the edges, and the clock-face orientation of each supra-aortic branch vessel is considered, 32 patients (97%) fit completely within these areas. An example of one of these patients is illustrated in Figure 4. The patient who could not be accommodated completely had a type I aortic arch configuration with a 10-mm-diameter IA located in a clock-face position at 13:25 when using the LSA as reference. The arc length calculated for this IA position was 20 mm laterally from the center of the LSA, such that only 50% of the 10-mm-diameter IA would be inside this pattern.

Discussion

This study defines 2 regions of the aortic arch from which 97% of supra-aortic branches originate in patients who had undergone a double-fenestrated total endovascular arch repair. This morphological data suggest that an off-the-shelf double-fenestrated thoracic stent-graft is at least conceptually possible. Industry could therefore use this "universal double fenestration pattern" to create a commercially available stent-graft for TEVAR allowing a proximal landing in zone 0.

While the use of a standard universal double fenestration pattern would not replace the need for meticulous preoperative planning, the advantages are clear. Avoiding the need for the operator to deploy and reassemble the stent-graft on a back table will shorten the time in the operating room and lessen the risk of contamination. It would also reduce potential errors in the selection of fenestration position by less experienced teams and will make the technique much simpler to reproduce, allowing treatment of more patients.

The variations of vessels arising from the aortic arch are numerous. The incidence of these variations in the aortic arch branching pattern in the general population has been investigated by a small number of studies performing postmortem examinations on a limited number of cases. The normal aortic arch pattern defined as type I includes from proximal to distal the IA, the LCCA, and the LSA. This pattern occurs 79.2% to 83.3%[7,10,11] of the time. The IA and the LCCA arising from the arch in a common trunk (most often termed a bovine arch[12]) is defined as type II and is the most common variation, with a range reported between 11% and 27%.[9,10,13,14]

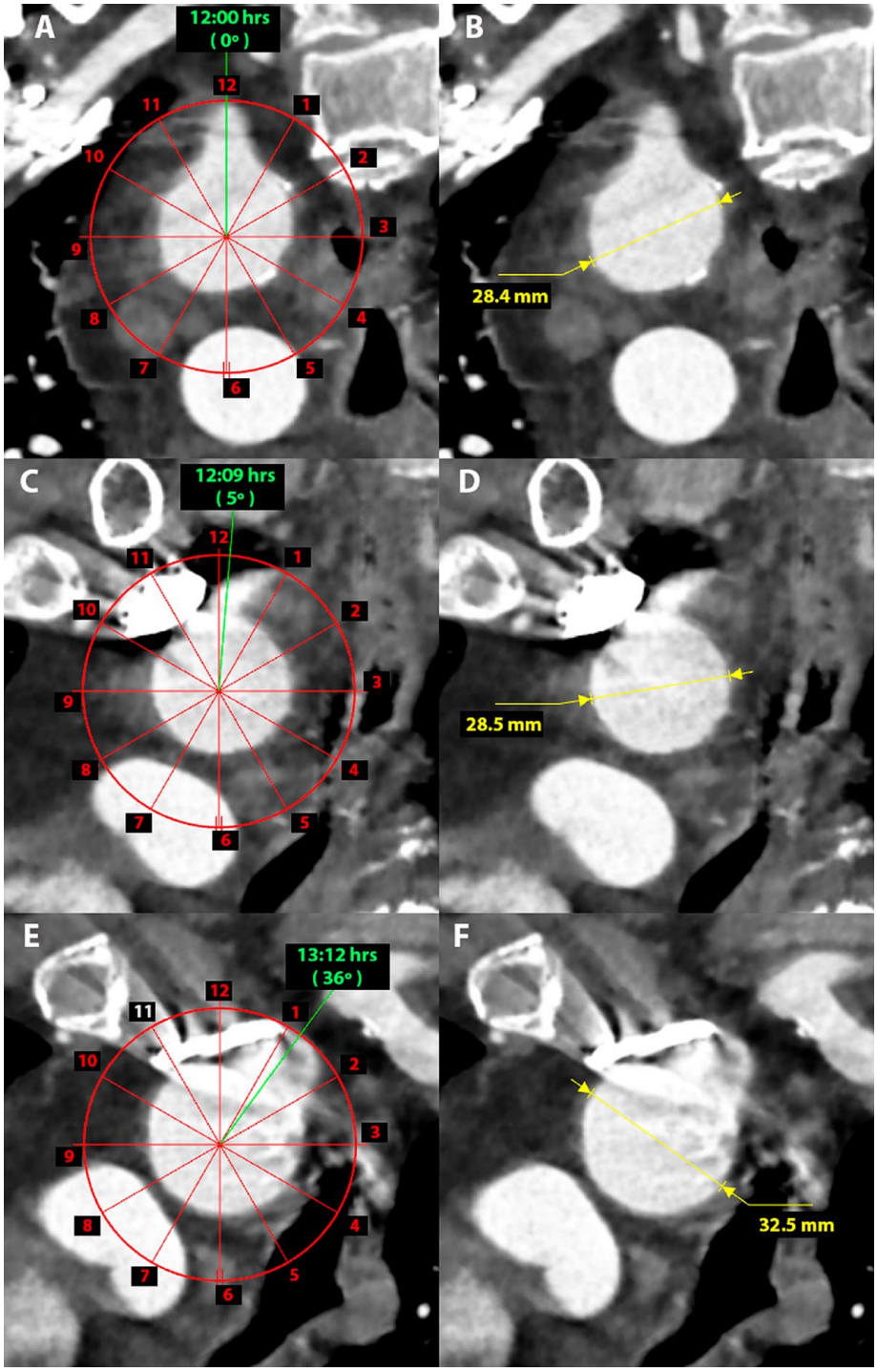

Figure 2. Green lines show the clock-face orientation of each supra-aortic branch vessel [A and B: left subclavian artery (LSA); C and D: left common carotid artery; E and F: innominate artery] using the center of the LSA as a reference point at 12 o'clock (0°). The yellow lines show the aortic diameter at the level of each branch vessel.

The second most common variant (2.5%[14] to 5.4%[7]) is a 4-vessel arch in which the left vertebral artery (LVA) originates from the arch between the LCCA and the LSA (type III). The coexistence of types II and III is defined as type IV. Type V involves an aberrant right subclavian artery that originates distal to the LSA and passes retropharyngeal. With the

Table 2. Frequency of Variations in the Aortic Arch Branching Pattern in 33 Patients Using the Natsis Classification.[9]

Type I	Normal aortic arch branching (1: IA, 2: LCCA, 3: LSA)	26 (79)
Type II	Bovine aortic arch (1: common IA and LCCA trunk, 2: LSA)	5 (15)
Type III	LVA (3) originating from aortic arch (1: IA; 2: LCCA, 4: LSA)	1 (3)
Type IV	Coexistence of type II and III (1: common IA and LCCA trunk, 2: LVA, 3: LSA)	0
Type V	Aberrant right subclavian artery (4; 1: RCCA, 2: LCCA, 3: LSA)	1 (3)
Type VI	Coexistence of bicarotid trunk (1) and ARSA (3); 2: LSA	0
Type VII	Absence of the IA (1: RSA, 2: RCCA; 3: LCCA; 4: LSA)	0
Type VIII	Thyroid ima artery (3) originating from the aortic arch (1: IA, 2: LCCA, 4: LSA)	0

Abbreviations: IA, innominate artery; LCCA, left common carotid artery; LSA, left subclavian artery; LVA, left vertebral artery; RCCA, right common carotid artery; RSA, right subclavian artery.

Table 3. Diameters, Lengths, and Clock-Face Orientation Measured at the Aortic Arch.[a]

Mid ascending aorta diameter, mm	35.7±3.7
Aortic diameter at the level of the IA, mm	34.2±4.5
Aortic diameter at the level of the LCCA, mm	33.3±6.7
Aortic diameter at the level of the LSA, mm	33.7±4.7
IA ostium diameter, mm	12.2±1.7
LCCA ostium diameter, mm	7.5±1.4
LSA ostium diameter, mm	8.0±0.8
Length from the center of the LSA to center of the LCCA, mm	15.9±2.5
Length from the center of the LCCA to the center of the IA, mm	12.1±3.0
Length from the proximal edge of the LSA to the distal edge of the LCCA, mm	7.7±2.4
Length from the distal edge of the LCCA to the proximal edge of the IA, mm	22.3±3.3
IA clock-face orientation with the center of the LSA as reference, h	12:50±0:35
LCCA clock-face orientation with the center of the LSA as reference, h	12:05±0:20

Abbreviations: IA, innominate artery; LCCA, left common carotid artery; LSA, left subclavian artery.
[a]Data are presented as the mean ± standard deviation.

exception of types I, II, and III, all the remaining variations (type IV, V, VI, VII, and VIII) are very rare, and most of them have an incidence of <1%.[9] Although the majority of the literature reports on patients without aortic lesions, similar incidences of these variations were found in our cohort. In addition to the variations already mentioned, the aortic arch also undergoes conformational change due to elongation with age,[15] and changes in incidence have been noted between different ethnic groups.[16]

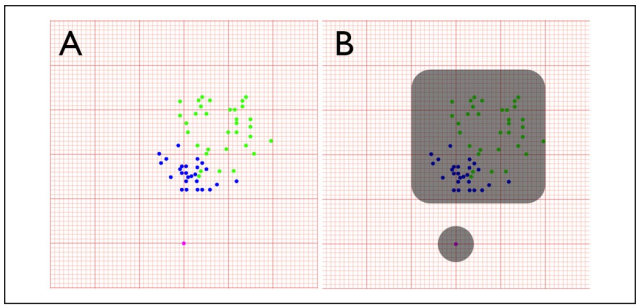

Figure 3. (A) The blue dots [center of the left common carotid artery (LCCA)] and green dots [center of the innominate artery (IA)] indicate the location of the artery in relation to a fixed point (purple dot) based on the center of the left subclavian artery (LSA). (B) IA (green dots) and LCCA (blue dots) arise from a common 30×30-mm area (gray square) in all patients. A second circular 8-mm-diameter area (gray) represents the center of the LSA (purple dot) in all patients. The background has 10 squares per centimeter.

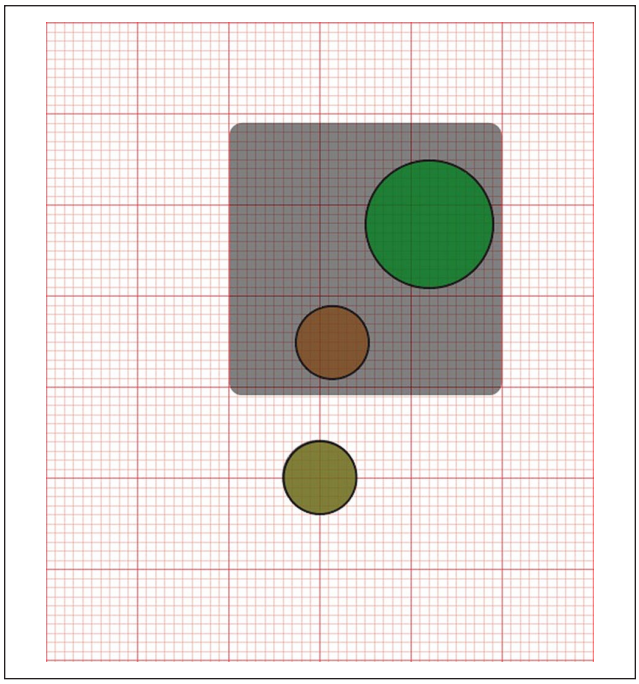

Figure 4. Graphic representation of measurements from a patient with all the supra-aortic branches inside the 2 predefined area (square and circular gray shadows). This patient has a 14-mm-diameter innominate artery (IA; green dot) at 13:15 o'clock, an 8-mm-diameter left common carotid artery (LCCA; orange dot) at 12:15 o'clock, and an 8-mm-diameter left subclavian artery (LSA; yellow dot) at 12:00 o'clock. The distance from the center of the LSA to the center of the LCCA is 15 mm, and the distance from the center of the LCCA to the center of the IA is 13 mm. The background has 10 squares per centimeter.

In 1969, Wright et al[17] reported measurements of the aortic arch in 100 fresh cadaveric specimens. The diameter of the ascending aorta proximal to the origin of IA was

23.0±1.37 mm. The ascending aortic diameters reported in our study were significantly larger, likely because our group of patients had existing aortic arch lesions that could increase proximal aortic diameters.[18] Wright and colleagues[17] also measured diameters at the origins of each supra-aortic branch reporting 12.5±1.25, 7.5±2.09, and 10.0±2.15 mm for the ostia of the IA, LCCA, and LSA, respectively. In a more recent study[19] in 60 male cadavers, means for the same branches were 9.43±2.17, 6.4±1.22, and 7.62±1.76 mm. We note that in our group the supra-aortic branch vessel diameters were closer to this latter report.

Our group of patients also had a smaller distance between the adjacent margins of the IA and LCCA than the distance between the margins of the LCCA and LSA. The aortic space between the IA and LCCA is small, sometimes extremely narrow, contrary to the space between the LCCA and LSA, which presents more like a "bridge." In all of our patients this bridge was ≥5 mm and also <20 mm, which is considered the minimum acceptable distance to ensure a seal in the proximal landing zone for TEVAR.[20] This result was expected because all patients in this series were treated with a double fenestration. Therefore, if they had pathology involving the LSA they would have been unlikely to be successfully treated by simply extending a thoracic stent-graft to the level of the LSA.

The literature is sparse with regard to the description of clock-face orientation of the supra-aortic branch vessel. The majority of studies are in fresh cadavers and report only distances from the greater curve or from the mid vertebral line to the edge of each branch vessel. Malkawi et al[21] reported clock-face orientation of the center of the LCCA and the LSA ostium using the IA as a reference point. They described that the majority (80%) of patients had clock-face positions of the LCCA and LSA ostium within 15° of each other. The mean degree of separation of the supra-aortic branch vessels observed in our group of patients were 3° between the LSA and LCCA and 22° between LCCA and IA. Alberta et al[18] reported the clock-face positions of the IA, LCCA, and LSA using the greater curve as reference in 210 patients with traumatic aortic injury, dissection, and aneurysm. The most commonly observed clock-face position for the IA was at 12:30 (12:45 in trauma and aneurysm patients and 12:15 in dissection patients). In all 3 patient populations, the most common LCCA position was 12 o'clock. The most common position of the LSA in trauma and dissection patient was 12 o'clock and 12:15 in aneurysm patients. Our 33 patients with different aortic arch pathologies using the LSA as reference are consistent with this report. For practical reasons we prefer using the center of the LSA instead of the greater curve as a reference in determining clock-face position of supra-aortic branches because in our opinion it is simpler and easier to reproduce.

Limitations

The study is limited by the low number of patients, but the measurements are similar to larger published studies. This similarity suggests that the universal double fenestration pattern accommodating the anatomy of our group of patients would also fit the majority of patients reported in the large anatomical series.

Conclusion

Our study defined 2 areas of the aortic arch in which all the supra-aortic branches originate in 97% of patients. This pattern could be used by industry to design a stent-graft with 2 universal fenestrations for complete endovascular arch repair. This off-the-shelf universal double-fenestrated stent-graft can avoid some of the challenges and concerns surrounding PMEGs, making the technique simpler and more reproducible for total endovascular aortic repair.

Declaration of Conflicting Interests[GQ: 2]

The author(s) declared no potential conflicts of interest with respect to the research, authorship, and/or publication of this article.

Funding

The author(s) received no financial support for the research, authorship, and/or publication of this article.

ORCID iD[GQ: 3]

Lucien Chassin-Trubert https://orcid.org/0000-0003-2108-4488
Youcef Lounes https://orcid.org/0000-0001-9502-2808
Ludovic Canaud https://orcid.org/0000-0001-6751-1188

Supplemental Material

The video is available at http://journals.sagepub.com/doi/suppl/1526602820931787

References

1. Canaud L, Baba T, Gandet T, et al. Physician modified thoracic stent-grafts for the treatment of aortic arch lesions. *J Endovasc Ther*. 2017;24:542–548.
2. Canaud L, Morishita K, Gandet T, et al. Homemade fenestrated stent-graft for thoracic endovascular aortic repair of zone 2 aortic lesions. *J Thorac Cardiovasc Surg*. 2018;155:488–493.
3. Kurimoto Y, Maruyama R, Ujihira K, et al. Thoracic endovascular aortic repair for challenging aortic arch diseases using fenestrated stent grafts from zone 0. *Ann Thorac Surg*. 2015;100:24–32.
4. Canaud L, Ozdemir B, Chassin-Trubert L, et al. Double homemade fenestrated stent graft for total endovascular aortic arch repair. *J Vasc Surg*. 2019;70:1031–1038.
5. Canaud L, Chassin-Trubert L, Ozdemir B, et al. Homemade fenestrated stent graft for complete endovascular of aortic arch dissections. *J Endovasc Ther*. 2019;26:645–651.

6. Chassin-Trubert L, Mandelli M, Ozdemir BA, et al. Midterm follow-up of fenestrated and scalloped physician-modified endovascular grafts for zone 2 TEVAR. *J Endovasc Ther*. 2020;27:xx–xx[AQ: 1]
7. Thomson A. Third annual report of committee of collective investigation of anatomical society of Great Britain and Ireland for the year 1891-92. *J Anat Physiol*. 1893;27:183–194.
8. Goldstein S, Evangelista A, Abbara S, et al. Multimodality imaging of diseases of the thoracic aorta in adults: from the American Society of Echocardiography and the European Association of Cardiovascular Imaging endorsed by the Society of Cardiovascular Computed Tomography and Society for Cardiovascular Magnetic Resonance. *J Am Soc Echocardiogr*. 2015;28:119–182.
9. Natsis K, Tsitouridis I, Didagelos M, et al. Anatomical variations in the branches of the human aortic arch in 633 angiographies: clinical significances and literature review. *Surg Radiol Anat*. 2009;31:319–323.
10. Karacan A, Turkvatan A, Karacan K. Anatomical variations of aortic arch branching: evaluation with computed tomographic angiography. *Cardiol Young*. 2014;24:485–493.
11. Adachi B. Das arterienssystem der Japaner. Kyoto, Japan: Kenkyusha; 1928;29–41.
12. Layton K, Kallmes D, Cloft H, et al. Bovine aortic arch variant in humans: clarifications of a common misnomer. *AJNR Am J Neuroradiol*. 2006;27:1541–1542.
13. Quain R. *Anatomy of the Arteries of the Human Body*. London: Taylor & Walton; 1844:538–543.
14. Liechty J, Shields T, Anson B. Variations pertaining to the aortic arches and their branches. *Q Bull Nortwest Univ Med Sch*. 1957;31:136–143.
15. Pearce W, Slaughter M, LeMaire S, et al. Aortic diameter as a function of age, gender, and body surface area. *Surgery*. 1993;114:691–697.
16. Williams G, Aff H, Schmeckebier M, et al. Variations in the arrangement of the branches arising from the aortic arch in American whites and negroes. *Anat Rec*. 1932;54:247–251.
17. Wright N. Dissection study and mensuration of the human aortic arch. *J Anat*. 1969;104:377–385.
18. Alberta H, Takayama T, Smits T, et al. Aortic arch morphology and aortic length in patients with dissection, traumatic, and aneurysmal disease. *Eur J Vasc Endovasc Surg*. 2015;50:754–760.
19. Chhabra K, Saini K. Morphometric study of arch of aorta and its branches. *Int J Anat*. 2015;3:1079–1083.
20. Czerny M, Funovics M, Sodeck G, et al. Long-term results of thoracic endovascular aortic repair in atherosclerotic aneurysms involving the descending aorta. *J Thorac Cardiovasc Surg*. 2010;140:179–184.
21. Malkawi A, Hinchliffe J, Yates M, et al. Morphology of aortic arch pathology: implications for endovascular repair. *J Endovasc Ther*. 2010;17:474–479.